

A Novel Method for Recognition of Carotid Artery in Carotid Ultrasound Images

¹Aneesha Ali K.

Department of Electronics and Communication Engineering
TKM Institute of Technology
Karuvelil, Kollam.

²Asha A. S.

Department of Electronics and Communication Engineering
TKM Institute of Technology
Karuvelil, Kollam.

Abstract - The aim of this paper is to develop a multiresolution recognition system for high-performance intima-media thickness (IMT) measurement in longitudinal ultrasound carotid imaging. Atherosclerosis is the thickening and narrowing of the arteries due to formation of plaque on the walls of the artery. Intima-media thickness (IMT) is an early indicator of atherosclerosis. Recognition of carotid artery is the primary step to the measurement technique. It comprises edge estimation for the far adventitia (AD_F) borders along the carotid artery (CA). The longitudinal ultrasound image of the carotid artery consists of a near and a far wall of the carotid artery and are displayed as two bright white lines. The outer layer of far wall is the far adventitia. AD_F border is estimated using the derivative of Gaussian kernel. The estimated border is traced by a heuristic approach.

Keywords – Atherosclerosis, intima-media thickness, first-order Gaussian derivative.

I. INTRODUCTION

Atherosclerosis is an inflammatory disease that often begins early in life with impairment of endothelial function, which leads to the formation of lesions in large and medium elastic and muscular arteries. It is one of the leading causes of stroke and is the first clinical manifestation of cardiovascular disease. In the early stages of arterial wall thickening and plaque formation, no luminal changes are seen because the arterial wall expands to compensate. The intima-media thickness (IMT) of the common carotid artery (CCA) is the most widely used marker for the monitoring of the atherosclerotic process and assessment of cardiovascular diseases (CVDs) risk. IMT is usually measured by using ultrasound imaging. The anatomical positioning and the relatively big diameter make the ultrasound examination of the carotid arteries (CAs) very simple and effective.

In human anatomy, the left and right common carotid arteries are arteries that supply the head and neck with oxygenated blood. The atherosclerotic process refers to the degeneration of the arterial wall and the deposition of lipids and other blood-borne material within the arterial wall of almost all vascular territories. In the early stages of arterial wall thickening and plaque formation, no luminal changes are seen because the arterial wall expands to compensate. As atherosclerosis is a slow process,

collecting clinical end-point data takes a long time and provides information mainly on the late stages of vascular disease, which makes cause and effect relationships difficult to unravel. The atherosclerotic process can be monitored in its early stages by measuring intima-media thickness. IMT is usually measured by using ultrasonography, as it can depict all stages of atherosclerotic arterial wall changes.

Normally, a trained sonographer manually measures the IMT from longitudinal projections of the CA, but these manual measurement methods are time consuming, subjective, and tedious. In addition, due to the lack of standardization, the differences in the gain settings, scanner performances, and the training of the clinicians all add up to cause significant variability, particularly in large and multi center studies. Since the early 1990s, different computer techniques have been developed for the recognition of the CA wall in longitudinal images (a state-of-the-art review on the most used image processing techniques in carotid wall segmentation and IMT measurement can be found in a recent review by Molinari *et al.* [2]).

The main objective of this paper is to develop an automated recognition system for high performance Intima-Media thickness (IMT) measurement in longitudinal ultrasound carotid imaging.

II. RECOGNITION SYSTEM

The recognition of carotid artery in an image frame consists of steps such as, downsampling by a factor 2, speckle noise attenuation, edge estimation (AD_F border estimation), thresholding and upsampling of AD_F .

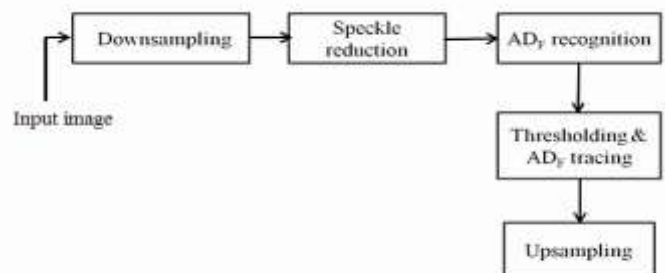


Fig. 1. Block diagram

The carotid ultrasound image is acquired and cropped to remove the nonrelevant information in the image. The

cropped image undergoes the following steps. The identification of the carotid artery (CA) in the image frame is the estimation of the edges of the far adventitia (AD_F) borders using a scale-space concept in a multiresolution framework.

The image was first downsampled by a factor of 2 (i.e., the number of rows and columns of the image was halved). The bicubic method was used to resize the image. In bicubic method of resizing, the image was first filtered using a low pass filter to avoid aliasing. Then it estimates the intensity value at a pixel in the destination image by an average of 16 pixels surrounding the closest corresponding pixel in the source image. i.e., the intensity value is computed by considering the 16 pixels close to the considered one. The multiresolution method prepares the vessel wall's edge boundary such that the vessel wall thickness tends to be equivalent to the scale of the Gaussian kernels. This infrastructure will allow the scale-space-based vascular edge segmentation methods applicable to the vessel wall for edge detection, which, in turn, is necessary for locating the CA in the image frame.

Speckle is a form of multiplicative noise, which corrupts medical ultrasound imaging making visual observation difficult and therefore should be filtered out. Speckle noise was attenuated by using a first-order local statistics filter and also with a median filter. The first-order local statistics filter uses the first order statistics such as the variance and the mean of the neighborhood. The algorithm in this class is described as

$$f_{i,j} = g + k_{i,j}(g_{i,j} - g)$$

where $f_{i,j}$ is the estimated noise-free pixel value, $g_{i,j}$ is the noisy pixel value in the moving window, g is the local mean value. $k_{i,j}$ is a weighting factor, and i, j , are the pixel coordinates.

The factor $k_{i,j}$ is a function of the local statistics in a moving window and is given as

$$k_{i,j} = (1 - g^2\sigma^2) / (\sigma^2(1 + \sigma_n^2))$$

The values σ^2 and σ_n^2 represent the variance in the moving window and the variance of noise in the whole image, respectively. If the value of $k_{i,j}$ is 1 (in edge areas) this will result to an unchanged pixel, and a value of 0 (in uniform areas) replaces the actual pixel by the local average, g , over a small region of interest.

III. AD_F RECOGNITION

The far adventitia (AD_F) recognition is the process of estimating the edges of distal wall (adventitia) of the carotid artery. In order to estimate the edges, a first order derivative of a Gaussian kernel with scale σ was used. The despeckled image was filtered by first order derivative of a Gaussian kernel using convolution. i.e.,

$$F(x, \sigma) = \sigma \cdot I(x) \otimes \frac{\partial G}{\partial x}(x, \sigma)$$

where $\frac{\partial G}{\partial x}$ is the first-order derivative of Gaussian kernel $G(x, \sigma)$, $F(x, \sigma)$ is the filtered image. The Gaussian kernel was defined as

$$G(x, \sigma) = \frac{1}{2\pi\sigma^2} e^{-|x|^2/2\sigma^2}$$

The scale parameter of the Gaussian derivative kernel was taken to be equal to 8 pixels, i.e., twice the expected dimension of the IMT value in an original fine-resolution image. In fact, an average IMT value of, e.g., 1 mm corresponds to about 12–16 pixels in the original image scale and, consequently, to 6–8 pixels in the coarse or downsampled image.

The system is based on the hypothesis that the far wall has the highest intensity. So the proximal (near) and distal (far) walls are intensity maxima saturated to the value of 255 in the filtered image. The intensity profile of each column (from the upper to the lower edge of the image) of the filtered image was estimated, so that the intensity value of 255 with highest row index of each column corresponds to the AD_F along the carotid artery.

Thresholding consists of segmenting an image into two regions a particle region and a background region. It is the process of setting all pixels that belong to a gray level to white and setting all other pixels in the image to black. Thus the filtered image was converted to binary image for tracing the borders. To automatically trace the profile of the distal (far) wall, a heuristic search was applied to the intensity profile of each column in the binary image.

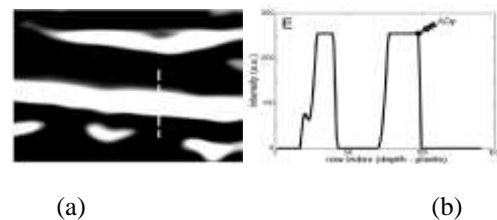


Fig. 2. (a) Image after convolution with a first order Gaussian derivative. (b) Intensity profile of the column indicated by the vertical dashed line

Starting from the bottom of the image (i.e., from the pixel with the higher row index, note that (0,0) is the top left-hand corner of the image), search for the first white region where the width of the region is W_{search} pixels. The white region corresponding to the AD_F wall has a width equal to σ , which is the same size of the Gaussian kernel. Therefore, a threshold value of 16 was the optimal choice for the input image and ensured the correct identification of the AD_F in the image. On taking the lower values, it leads to the identification of other structures that were not the far wall; such structures can be present below the carotid far wall (i.e., they are usually deeper than the artery and correspond to the neck structures around the trachea).

The deepest point of this region (i.e., the pixel with the higher row index) marked the position of the AD_F layer on that column. The sequence of points resulting from the heuristic search for each of the image columns constituted the overall automated AD tracing. The heuristic search

procedure combined with decimation ensured a faster and efficient strategy for carotid detection.

The AD_F profile was then upsampled to the original fine scale and superimposed over the original cropped image for both visualization and determination of the ROI for the segmentation (or calibration) phase. The image was upsampled by a factor 2 (i.e., the number of rows and columns of the image was doubled).

IV. RESULTS AND DISCUSSION

The carotid artery has been recognized by tracing the AD_F border using a first order derivative of a Gaussian kernel and heuristic approach. Simulation is done in MATLAB R2013a. The simulation results are given below.

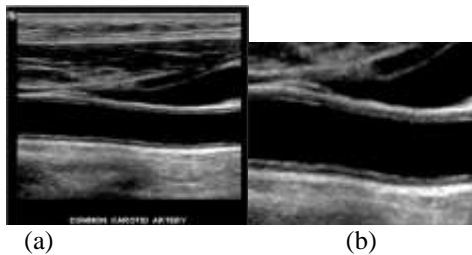


Fig. 3. (a) Input ultrasound image. (b) Cropped image.

The input image contains some nonrelevant information, such as the surrounding black frame containing text data. So it was removed prior to the recognition process of the carotid artery. Fig. 3(b) shows the cropped image, without any black frame and text data.

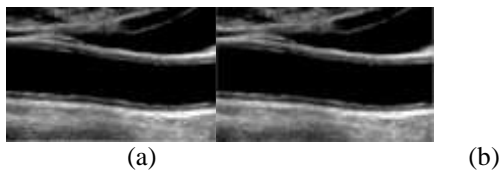


Fig. 4(a)Downsampled image. (b) Despeckled image

The despeckled image was convoluted with a first order Gaussian derivative with $\sigma=16$. This was done to identify edges, as the aim was to find edges of far adventitia borders of the carotid artery for the recognition and tracing AD_F .

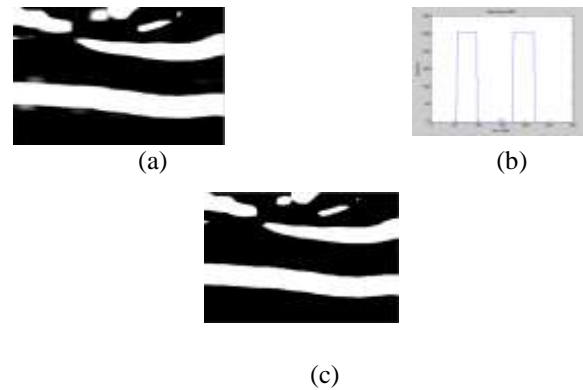


Fig. 5(a) Image after convolution with a first order Gaussian derivative. (b)Intensityprofile of a column. (c)Binary image.

The trial and error procedure was applied in the binary image and located the AD_F border along carotid artery. AD_F profile was overlaid on the cropped image. Fig. 6. shows the cropped image with the AD_F profile overlaid. The black curve indicates the AD_F wall.

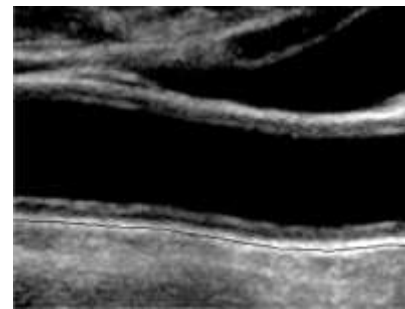


Fig. 6. Cropped image with AD_F profile overlaid

V. CONCLUSION

Atherosclerosis can be monitored in its early stages by measuring intima-media thickness. IMT measurement involves the recognition of carotid artery and segmentation of the carotid wall. The recognition of carotid artery is the recognition of far wall of the carotid artery. A new carotid artery recognition system was implemented based on scale-space paradigm. In this work, the identification of the carotid artery (CA) in the image frame was done by estimating the edge of the far adventitia (AD_F) wall using a scale-space concept and heuristic approach. The edge was detected using the first order derivative of a Gaussian kernel. As a part of pre-processing, the image was downsampled and speckle noise was attenuated for faster computation and to reduce the complexity. The median filter is better than the first order local statistics filter for speckle noise attenuation, when computation time was compared. The despeckled image was convoluted with a first order Gaussian derivative to get the edges of far adventitia borders of the carotid artery. A trial and error procedure was applied and located the AD_F border along carotid artery. AD_F profile was overlaid on the cropped image. As time and complexity are concerned this method of recognition is better than existing ones.

REFERENCES

- [1] Filippo Molinari, Constantinos S. Pattichis, Guang Zeng, Luca Saba, U. Rajendra Acharya, Roberto Sanfilippo, Andrew Nicolaides, and Jasjit S. Suri, "Completely Automated Multiresolution Edge Snapper—A New Technique for an Accurate Carotid Ultrasound IMT Measurement: Clinical Validation and Benchmarking on a Multi Institutional Database", *IEEE Transactions On Image Processing*, vol. 21, no. 3, March 2012 .
- [2] F. Molinari, G. Zeng, and J. S. Suri, "A state of the art review on intima-media thickness (IMT) measurement and wall segmentation techniques for carotid ultrasound," *Comput. Methods Programs Biomed.*, vol. 100, no. 3, pp. 201–221, Dec. 2010.
- [3] F. Molinari, G. Zeng, and J. S. Suri, "An integrated approach to computer-based automated tracing and its validation for 200 common carotid arterial wall ultrasound images: A new technique," *J. Ultrasound Med.*, vol. 29, no. 3, pp. 399–418, Mar. 2010.
- [4] R. Rocha, A. Campilho, J. Silva, E. Azevedo, and R. Santos, "Segmentation of the carotid intima-media region in B-mode ultrasound images," *Image Vis. Comput.*, vol. 28, no. 4, pp. 614–625, Apr. 2010.
- [5] F. Destrempes, J. Meunier, M. F. Giroux, G. Soulez, and G. Cloutier, "Segmentation in ultrasonic B-mode images of healthy carotid arteries using mixtures of Nakagami distributions and stochastic optimization," *IEEE Trans. Med. Imag.*, vol. 28, no. 2, pp. 215–229, Feb. 2009.
- [6] A. C. Rossi, P. J. Brands, and A. P. Hoeks, "Automatic recognition of the common carotid artery in longitudinal ultrasound B-mode scans," *Med. Image Anal.*, vol. 12, no. 6, pp. 653–665, Dec. 2008.
- [7] S. Golemati, J. Stoitsis, E. G. Sifakis, T. Balkizas, and K. S. Nikita, "Using the Hough transform to segment ultrasound images of longitudinal and transverse sections of the carotid artery", *Ultrasound in Med. & Biol.*, Vol. 33, No. 12, pp. 1918–1932, Dec. 2007.
- [8] S. Delsanto, F. Molinari, P. Giustetto, W. Liboni, S. Badalamenti, and J. S. Suri, "Characterization of a completely user-independent algorithm for carotid artery segmentation in 2-D ultrasound images," *IEEE Trans. Instrum. Meas.*, vol. 56, no. 4, pp. 1265–1274, Aug. 2007.
- [9] C. P. Loizou, C. S. Pattichis, M. Pantziaris, T. Tyllis, and A. Nicolaides, "Snakes based segmentation of the common carotid artery intima media," *Med. Biol. Eng. Comput.*, vol. 45, no. 1, pp. 35–49, Jan. 2007.
- [10] C. P. Loizou, C. S. Pattichis, M. Pantziaris, T. Tyllis, and A. Nicolaides, "Quality evaluation of ultrasound imaging in the carotid artery based on normalization and speckle reduction filtering", *Med. Biol. Eng. Comput.*, Vol. 44, pp. 414–426, May 2006.
- [11] D. C. Cheng, A. Schmidt-Trucksass, K. S. Cheng, and H. Burkhardt, "Using snakes to detect the intimal and adventitial layers of the common carotid artery wall in sonographic images," *Comput. Methods Programs Biomed.*, vol. 67, no. 1, pp. 27–37, Jan. 2002.
- [12] I. Wendelhag, Q. Liang, T. Gustavsson, J. Wikstrand, "A new automated computerized analyzing system simplifies readings and reduces the variability in ultrasound measurement of intima-media thickness," *Stroke* 28 (11) (1997) 2195–2200.