

Dental Panoramic Radiographs in Prediction of Osteoporosis in Postmenopausal Women

Polavarapu Divyasree¹, Kathirvelu. D²

¹M-Tech, Department of Biomedical Engineering

²Assistant professor, Department of Biomedical Engineering
SRM University, Chennai, India

Abstract—Osteoporosis is a skeletal disorder characterized by low bone mass and micro-architectural deterioration, with a resulting increase in bone fragility and susceptibility to fracture. Computer-aided diagnosis system is designed to measure mandibular inferior cortical width on dental panoramic radiographs and evaluation of the system efficacy in indentifying postmenopausal women with low skeletal bone mineral density. Mandibular inferior cortical width was measured by enhancing the original panoramic image, determining cortical boundaries, and evaluating distance between the upper and the lower boundaries in the region of interest by using the MATLAB (Matrix Laboratory) software. The distance measured is compared with the DXA (dual energy absorptiometry) scan report to determine the osteoporosis.

Keywords—Osteoporosis, Low bone mineral density, Panoramic radiograph, Mandibular cortical width, Matlab, DXA.

I. INTRODUCTION

Osteoporosis is a skeletal disorder characterized by low bone mass density micro-architectural deterioration, with a resulting increase in bone density fragility and susceptibility to fracture. The bone strength is determined by skeletal bone mineral density (BMD) and by factors determining bone quality, such as bone turnover rate, BMD measurement of the general skeleton is an important indicator of risk of fractures for individuals [1].

Menopause is a major risk factor for osteoporosis, and most postmenopausal women are at risk of osteoporosis and consequent fractures. Because at this stage the calcium in the bone decreases and fractures of the bone occurs. Fractures contribute to increased medical costs and incremental risks of morbidity and mortality. Osteoporotic hip fractures are strongly considered, it cause increased risk of mortality and a decreased quality of life [2]. Screening strategies for osteoporosis has been improved and the use of bisphosphonates for the osteoporosis was approved after 1996 by the Food and Drug Administration. This clearly indicates that the early detection of individuals at risk of osteoporotic fractures and early intervention can help in reduce of these fractures, especially the hip fractures.

A new screening strategy for determining the risk of osteoporotic fractures in postmenopausal women is needed to reduce the number of osteoporotic fractures in many

countries, where the number of osteoporotic fractures continues to increase. Measuring the mandibular inferior cortical width (MCW) below the mental foramen of the mandible on dental panoramic radiographs [3].

II. MATERIALS AND METHODS

A panoramic radiograph (also termed panorex, dental panoramic radiograph, orthopantomogram or orthopantomograph, and sometimes abbreviated as PAN, DPR, OPT or OPG), is a panoramic scanning dental X-ray of the upper and lower jaw. It shows a two-dimensional view of a half-circle from ear to ear. An OPG relies on tomography i.e. images of specific radiographic planes are taken to make up the larger panoramic image where the maxilla and mandible are in the focal trough and the structures, superficial and deep to the trough, are blurred. It is taken for the postmenopausal women with the age greater than forty seven.

BMD at the AP spine by dual-energy X-ray absorptiometry (DXA) (DPX-alpha; Lunar, Madison, WI, USA). The patients were classified as normal (T-score: >-1) standard deviation [SD], osteopenic (T-score: -1 to $2.5SD$), or osteoporotic (T-score: $<-2.5SD$) at each skeletal site according to the World Health Organization (WHO) criteria [4].

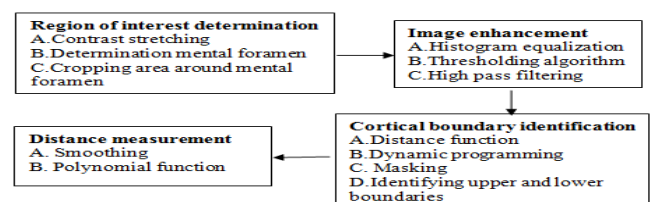


Figure 1. Schematic diagram of cortical width measurement

ROI determination

The original image is contrast stretched and then the area around mental foramen is cropped. The mental foramen is an opening on the lateral part of the mandible, inferior to the second premolar. The area involved in the lower border of the mandibular cortex below the mental foramen was

cropped manually on the right and left sides and was considered as the ROI (region of interest). Contrast of an image was increased by using the contrast stretching method [5].

Image enhancement

The enhancement process provides better inputs for automated image-processing image by manipulating the image with software. It is the process of externally, compression, filtering, extraction, selection, correlation, convolution, or transformations between domains.

The first step in image enhancement to obtain new enhanced images with a uniform histogram, it is obtained using histogram equalization method. Then thresholding is used to separate the object pixel values greater than a specified threshold value as the foreground, and those lesser than this threshold value as the background.

A clustering Thresholding algorithm, i.e. Otsu method is applied to separate the image pixels into the foreground and background. In this Thresholding is based on intraclass and interclass variances of the pixel values and binary images are generated with respect to the region of interest. Again gray level image is obtained by multiplying this binary image with the original image of the desired ROI, it generates an image that removes the background and preserves all gray levels considered as the foreground. An automatic Thresholding method is applied to maximize the separability of the resultant classes in gray levels [7].

High pass filtering

High-pass filtering sharpens the boundary along the cortical bone and also eliminates some features. To overcome this low-pass filter is used to generate the low-frequency image. This low-frequency image is then subtracted from the original image which results high frequency image. Again this gray scale image is binarized using Thresholding.

Cortical width measurement

The cortical boundaries of the mandibles are unclear because of multiple connections with the trabecular bone. To get this boundaries clear eight neighborhood distance functions (ENDF) are used to estimate the cortical width [8]. The distance is measured in pixels.

Distance measurement

The last step involves measuring the distance between the upper and lower boundaries of the cortical bone. Smoothing is done by using the filter and the distance between the upper and lower boundaries is measured.

III. RESULTS

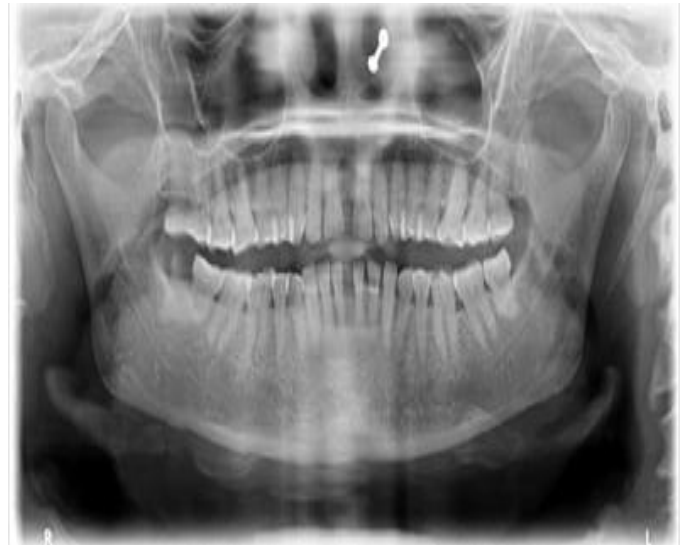

Figure 2 original image



Figure 3 Cropped image




Figure 4 Histogram equalized image



Figure 5 Clustered image



Figure 6 Distance transform of the image



Figure 7 Smoothing image

Distance points
 $P = 102.000, 90.000$
 $D = 12.000$ in pixels

IV. STATISTICAL ANALYSES

Group	Mean cortical width(mm)	BMD(g/cm ²)
Normal	3.439	1.241
Osteopenia	2.645	0.965
Osteoporosis	1.479	0.657

Table 1 Comparison of BMD values

This table tells the comparison of the cortical distance with the BMD values taken by the DXA scan.

Discussion

The computer aided system which is developed for identifying postmenopausal women with low-skeletal BMD (bone mineral density) measures the MCW between the upper and lower boundaries of the cortical bone. Computer aided system can directly assesses the bones on radiographs and reduces the measurement errors. It utilizes digital dental panoramic radiographs for identifying risk of osteoporosis. Women aged 50 years and older, who were identified by their general dental, actually had osteopenia or osteoporosis [9]. By comparing the MCW measured by our CAD system with the digital dental panoramic radiographs taken and the bmd values taken by the DXA scan. This can reduce the positioning error or magnification effect.

The use of our CAD system by general dental practitioners might allow them to identify many patients with low-skeletal BMD and refer these patients to medical

professionals for further examination. This CAD system is a useful tool in screening for osteoporosis.

REFERENCES

- [1] National Institute of Health. Osteoporosis prevention, diagnosis and therapy. NIH Consens Statement 2000; 17: 1–45.
- [2] Johnell O, Kanis JA. An estimate of the worldwide prevalence and disability associated with osteoporotic fractures. *OsteoporosInt* 2006; 17: 1726–33.
- [3] Brauer CA, Coca-Perrillon M, Cutler DM, Rosen AB. Incidence and mortality of hip fractures in the United States. *JAMA* 2009; 302: 1573–9.
- [4] World Health Organization. Assessment of fracture risk and its application to screening for postmenopausal women osteoporosis. Geneva: WHO, 1994.
- [5] Kavitha MS, Samopa F, Asano A, Taguchi A, Sanada M: Computer-aided measurement of mandibular cortical width on dental panoramic radiographs for identifying osteoporosis. *J InvClin Dent* 2011, 2:1-9
- [6] Gonzalez R, Woods R. Digital image processing, 3rd edn. New York: Addison-Wesley Publishing Company, 1992.
- [7] Arifin AZ, Asano A, Taguchi A et al. Computer-aided system for measuring the mandibular cortical width on dental panoramic radiographs in identifying postmenopausal women with low bone mineral density. *OsteoporosInt* 2006; 17: 7539.
- [8] Kavitha MS, Li L, Samopa F, Asano A, Taguchi A. Continuous measurement of mandibular cortical bone in dental panoramic radiographs for the diagnosis of osteoporosis using a clustering algorithm on histograms. *Proc Sec APSIPA ASC* 2010; 2: 560–7.
- [9] Hashimoto M, Yamanaka K, Shimosato T et al. Oral condition and health status of elderly 8020 achievers in Aichi prefecture. *Bull Tokyo Dent Coll* 2006; 47: 37–43.

IJERT