

# Exudates Segmentation in Retinal Fundus Images for the Detection of Diabetic Retinopathy

Soumil Chugh

Student, ECE Department

Chandigarh College of Engineering and Technology  
Chandigarh, India

Jaskirat Kaur, Deepti Mittal

Student, Assistant Professor

Thapar University  
Patiala, India

**Abstract**—Retinopathy is a disease showing no physical signs of occurrence with the major repercussion of loss of vision. The number of retinopathy cases is increasing with each year, which requires the evaluation of innumerable database. This has led to the evolution of various automated evaluation methods to follow up the retinal diseases. In this paper, a simpler automated approach is presented to detect diabetic retinopathy taking exudates into account. The earlier methods used direct segmentation, which generated mediocre results due to the fact that the texture of unhealthy areas is dissimilar. Therefore a different method is developed which uses homogeneity of healthy areas rather than unhealthy areas. In this method we first extract the healthy areas such as blood vessels by entropy thresholding method and optic disc using sobel filter method. Then the thresholding method is employed to segment the exudates in diabetic retinopathy images. Various qualities of retinal images are used and the results clearly show that the presented method performs better than the previous proposed methods for segmentation of exudates.

**Keywords**— *Retinal Images, Exudates, Optic Disc, Blood vessels*

## I. INTRODUCTION

Retinopathy is due to persistent or acute damage to the retina of the eye causing visual loss and blindness in some cases if medical treatment is not applied on time. Diabetic Retinopathy (DR) is an ocular testimony of diabetes, which affects up to 80 percent of all patients who have had diabetes for 10 years or more. Hence continuous monitoring is very important to diagnose the early symptoms so that timely effective treatment can be taken [1]. Elementary variations in the retina signify the presence of DR, which can be utilized in the automatic diagnosis of retinal images. Manual segmentation of the disease in retinal image is inconvenient, tedious and user may make mistakes during the process [2].

Therefore an automated system for the segmentation of disease could reduce the workload of the experts. Quality of the segmentation carried out depends on the quality of the image acquired and knowledge of the user. This system can evaluate the disease by segmenting the lesions and can be checked by the expert if further analysis is required upon the automatic segmentation of the lesion. Recent studies have shown that retinal diseases like DR can be examined from retinal fundus images [3,4]. Segmenting, measuring and monitoring the development of various degenerations

associated with DR such as hard exudates(HE), Cotton wool spots, micro aneurysms (MA) etc. is quite difficult due to their irregular structural variations.

Thus, successful segmentation of these irregular structures requires very complex and costly methods. On the other hand, healthy textures of retinal images have very regular patterns, and segmenting these regular patterns is easier than that of the irregular patterns. In this study, an inverse method for segmentation and measurement of lesions in retinal fundus images along with a simple method for blood vessel extraction using local thresholding are proposed.

## II. TECHNIQUES INVOLVED IN THE ANALYSIS OF EXUDATES

Since researchers started their work on automated diagnosis in ophthalmology [12,13], many methods have been developed for the detection of optic disc and blood vessels and their elimination to detect exudates in retinal images. Image thresholding, matched filter, mathematical models and edge detection methods were the most common methods used in segmentation [5,14]. Pattern recognition method, texture analysis, and mathematical morphology based methods have also been proposed for detecting DR lesions. These methods mainly focus on detection of only one type of anatomical structure such as OD or blood vessels [15,16]. Numerous other approaches were proposed for automatic segmentation of lesions of DR [17]. Most of the earlier segmentation methods if applied to detect one type of lesion it overlaps with other types of DR lesions as well. Also, various segmentation algorithms in proposed methods need large computational efforts and time.

Our algorithm involves several methods such as the optic disc detection and vessel elimination for the automatic segmentation of diabetic retinopathy. In these methods, green component is firstly extracted from the input RGB images, which are then converted into 8-bit grey scale images. The green channel illustrates the best contrast between the vessels and background while the red and blue ones tend to have more noise. Vessel elimination technique is applied to eliminate vessel structures from the retinal image. OD detection is carried out for locating OD and eliminating OD area from the segmented image.

Basic steps involved in our automatic segmentation method for detecting exudates are as following:

- Extracting green component in the retinal image
- Extracting vessels and eliminating them
- Detection of OD and eliminating the OD area
- Updating the lesions in the image
- Evaluating the results

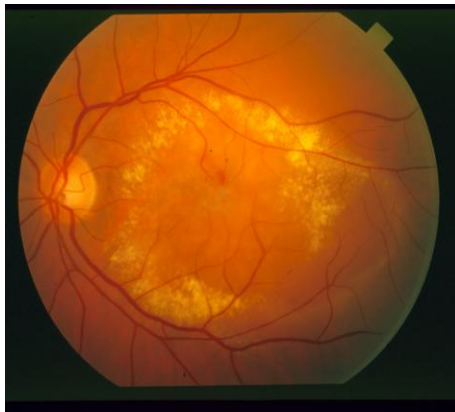

Fig.1. Original image

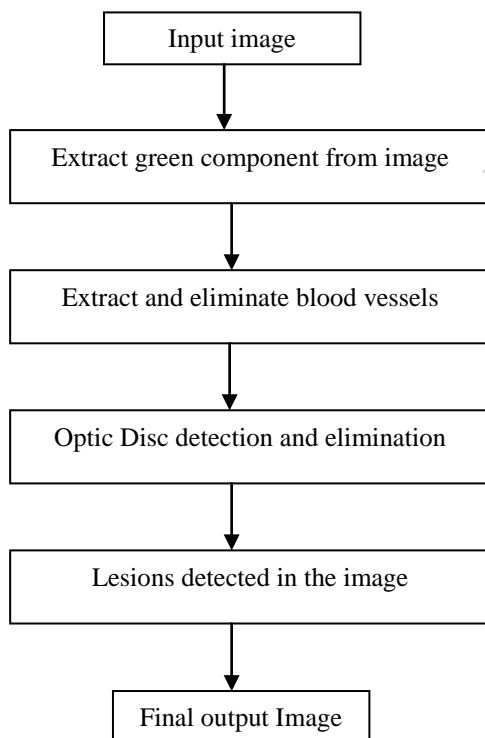


Fig.2. Flow chart of the method proposed

#### A. Elimination of blood vessels in retinal fundus images

A large number of methods have been proposed in literature for the detection and segmentation of vessels in retinal fundus images [6]. Retinal images consist of wide

variety of vessel structures and these should be eliminated properly to increase the accuracy of the final segmented image containing exudates. The grey scale image is processed by local thresholding process described in [7] in order to extract the blood vessels from the background. This algorithm takes into account the spatial distribution of grey levels because the image pixel intensities are not independent of each other. Two images with different spatial distribution but with same histogram will give different entropies. To fathom about transition of intensities between adjacent pixels, co-occurrence matrix of an image  $S[P \times Q]$  is used which shows the spatial structural information of an image. The co-occurrence matrix is considered asymmetric by taking into account the horizontally right and vertically lower transitions. Thus  $t_{ij}$  is defined by

$$t_{ij} = \sum_{m=1}^p \sum_{n=1}^q \alpha \quad (1)$$

$\alpha=0$  otherwise

The probability of co-occurrence  $p_{ij}$  of gray levels  $i$  and  $j$  can therefore be written as

$$p_{ij} = \frac{t_{ij}}{\sum_i \sum_j t_{ij}} \quad (2)$$

If  $w$ ,  $0 \leq w \leq L-1$  is a threshold then  $w$  can partition the co-occurrence matrix into 4 quadrants, namely E, F, G, and H. The following quantities are defined as

$$P_E = \sum_{i=0}^w \sum_{j=0}^w p_{ij} \quad (3)$$

$$P_H = \sum_{i=w+1}^{L-1} \sum_{j=w+1}^{L-1} p_{ij} \quad (4)$$

Normalizing the probabilities within each individual quadrant, such that the sum of the probabilities of each quadrant equals one, we get the following cell probabilities for different quadrants:

$$P_{ij}^E = \frac{p_{ij}}{p_z} = \frac{t_{ij} / \sum_{i=0}^{L-1} t_{ij}}{\sum_{i=0}^w \sum_{j=0}^w t_{ij} / \sum_{i=0}^{L-1} \sum_{j=0}^{L-1} t_{ij}} \quad (5)$$

For  $0 \leq i \leq w$ ,  $0 \leq j \leq w =$

$$\frac{t_{ij}}{\sum_{i=0}^w \sum_{j=0}^w t_{ij}} \quad (6)$$

$$P_{ij}^G = \frac{p_{ij}}{p_G} = \frac{p_{ij}}{\sum_{i=w+1}^{L-1} \sum_{j=w+1}^{L-1} t_{ij}} \quad (7)$$

The second-order entropy of the object can be defined as

$$H_E^2(w) = -\frac{1}{2} \sum_{i=0}^w \sum_{j=0}^w P_{ij}^E \log_2 P_{ij}^E \quad (8)$$

Similarly, the second-order entropy of the background can be written as

$$H_G^2(w) = -\frac{1}{2} \sum_{i=w+1}^{L-1} \sum_{j=0}^{L-1} P_{ij}^G \log_2 P_{ij}^G \quad (9)$$

Hence, the total second-order local entropy of the object and the background can be written as

$$H_T^2(w) = H_E^2(w) + H_G^2(w) \quad (10)$$

The resulting image after entropy thresholding and subtraction from the original image is shown below

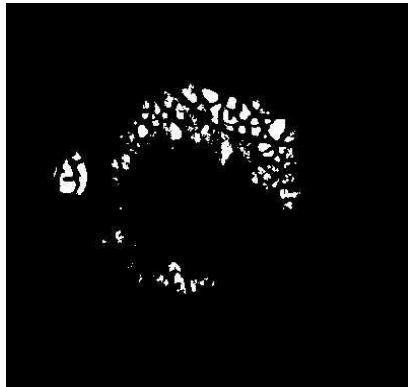


Fig.3. Image after thresholding

#### B. Method for locating and eliminating the Optic Disc

The location and detection of optic disc is crucial in analysis and quantification procedure of degenerations in retinal fundus images. The distinct properties of OD like high intensity; circular geometric structure etc. can be utilized in the detection. In the literature, many techniques are used to segment [8] and detect [9] OD in retinal fundus images. In this method modified sobel filter given by Eq. (11), that makes edges in the image clearer is employed

$$a(i, j) = \frac{\sum_{m=1}^n \text{abs}[a_{\text{ver}}(i+m, j)] + \text{abs}[a_{\text{hori}}(i, j+m)]}{n} \quad (11)$$

The image is filtered using modified sobel filter and high intensity areas are determined using the background image.

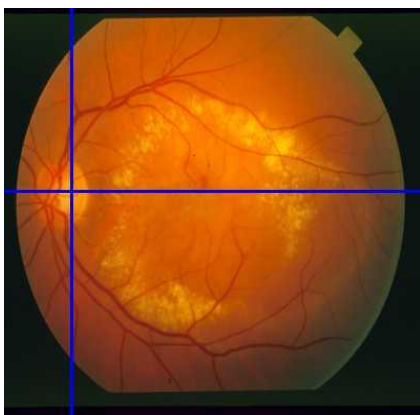


Fig.4. OD Detection

These high intensity areas are eliminated from the filtered image by examining the area around the current pixel value.

OD area may also be segmented as DR lesion and degeneration cannot be measured correctly. Hence OD region must be eliminated from the final image. Removal of optic disc from the original image results to the following image fig.5




Fig.5. OD Removal

#### C. Updating the lesions

Entropy thresholding is used to remove the vessels. The remaining areas after the segmentation of vessels are the dark lesions and considered as the degenerated area. Threshold value is set just below the intensity value of the background image. Therefore the pixels with lower intensity than the threshold value are set as degenerated area after the vessels are eliminated. These pixels are set to blue in the resulting image

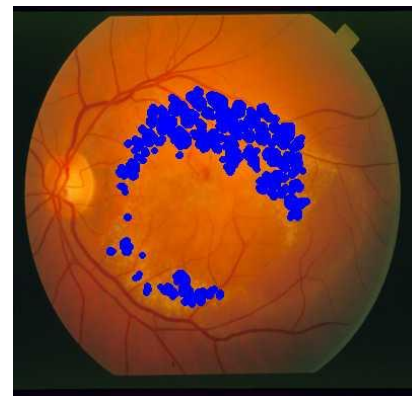


Fig.6. Final Output

### III. PARAMETERS USED IN PERFORMANCE EVALUATION

The need of automatic detection and segmentation of retinal diseases is raising on account of the increase in the number of retinal fundus images an ophthalmologist has to work on day to day basis. The method proposed here is able to automatically detect and segment the lesions that are a part of a litany of symptoms of diabetic retinopathy. The manual segmentation and measurement of the lesions is a conundrum

for most of the users and high amounts of proficiency is required to achieve high accuracy as described earlier [1]. Also various factors like quality of an image also effects the manual segmentation. In the proposed method the parameters used to evaluate the performance are mainly True Positive, True Negative, False Positive and False Negative. The widely used statistical performance parameters are sensitivity and specificity. Sensitivity equals the fraction of true positives correctly classified while Specificity is the fraction of true negatives correctly classified by a system.

$$\text{Sensitivity} = \frac{Tp}{Tp + Fn} \quad (12)$$

$$\text{Specificity} = \frac{Tn}{Tn + Fp} \quad (13)$$

#### IV. RESULTS

In our study, a total of 113 retinal fundus images with 400×400 pixels resolution as shown in Table I were used to evaluate the method proposed. The retinal images were obtained from digital fundus camera in SGHS hospital located in Sohana (Punjab). OD location and detection performance of the system was tested by using 47 retinal fundus images with apparent OD. To show the variations in the segmentation of DR, distributions of the degeneration portions in retinal images are shown in Table I. It is observed that most of the DR lesions are spread across the whole retinal fundus image.

TABLE.I DISTRIBUTION OF HE IN RETINAL FUNDUS IMAGES

Distributions of HE in Retinal Images		
	No. of Images	In %age
HE spread around Macula	28	24.77
HE spread around whole image	85	75.22
Total no. of Images	113	100

In order to evaluate the performance of the method proposed, we tested our system on retinal fundus images with different sizes of HE namely small, medium and large. The basic step in our method is to locate and detect the ODs in many different types of cases. Thus, all types of retinal fundus images are included in the measuring the performance of the system in OD localization and detection. On the contrary, only images with DR are used in measurement of the HE segmentation performance.

In the optic disk detection and location, mainly the results are obtained for the retinal images with DR. Results for detection of OD and elimination of OD area are given in Table II. The results depict about on an average 95.7% of the OD on the images with no, little or medium degeneration, are detected efficiently.

TABLE.II DETECTING AND LOCATING OD

OD No. of Images	Detecting and Locating OD		
	Precisely	Roughly	Wrongly
47 Images with clear OD	39	6	2
71 Images with non clear OD	54	14	3
Total %age	95.7% Located correctly		

The results of sensitivity and specificity are shown in Table III which helps in the evaluation of performance of detection of lesions. Throughout the paper, the threshold value was kept same and parameters mentioned above are used to generate consistent and comparable results. Therefore, minute under and over segmentations are encountered in some of the test cases. However the proposed technique is still quite efficient in detection and segmentation of lesions.

TABLE.III PERFORMANCE PARAMETES FOR DETECTING HE

	Hard Exudates	
	Sensitivity	Specificity
Images with small lesions	0.981	0.986
Images with medium lesions	0.972	0.998
Images with large lesions	0.984	0.998
Average	0.979	0.994

#### V. CONCLUSION

In the literature various methods provide different performances in extraction of blood vessel, Localization of the OD and segmentation of DR lesions. The accuracy of segmentation is 90% [10, 11] in various methods involving the user. The proposed method is evaluated on 100 retinal images giving better results than other methods. The processing time for complete analysis is around 8.9 seconds without any user involvement. This proposed approach has also the ability to remove blood vessels in the retinal images, and it also eliminates the OD area to measure lesions correctly

#### VI. REFERENCES

- [1] M. Wilson, P. Soliz, S.C. Nemeth, "Computer-aided methods for quantitative assessment of longitudinal changes in retinal images resending with maculopathy," Medical Imaging 4681, pp. 150-170, (2002).
- [2] T. Smith, V. Sivagnanavel, J.K. Chan, et al., "An inter institutional comparative study of drusen segmentation and quantification using a digital technique of fundus background reconstruction," Investigative Ophthalmology & Visual Science 45 (2004).
- [3] K. Rapantzikos, M. Zervakis, K. Balas, "Detection and segmentation of drusen deposits on human retina: potential in the diagnosis of age-related macular degeneration," Medical Image Analysis, vol. pp. 95-108 (2003).
- [4] R.T. Smith, J.K. Chan, T. Nagasaki, et al., "Automated detection of macular drusen using geometric background leveling and threshold selection," Archives of Ophthalmology, vol.23 pp.200-206 (2005).
- [5] A.W. Reza, C. Eswaran, S. Hati, "Diabetic retinopathy: a quadtree based blood vessel detection algorithm using RGB components in fundus images," Journal of Medical Systems vol.32 pp.147-155 (2008)
- [6] O. Chutatape, L. Zheng, S.M. Krishnan, "Retinal blood vessel detection and tracking by matched Gaussian and kalman filters," A tutorial

- review, in: Proc. 20th IEEE Conf. on Engineering in Medicine and Biology Society, vol. pp. 3144-3149 (1998).
- [7] N. R. Pal and S. K. Pal, "Entropic thresholding," *Sigmlpmsprocessing*, vol. 16, pp. 97- 108, 1989.
- [8] S.S. Lee, M. Rajeswari, D. Ramachandram, B. Shaharuddin, "Screening of diabetic retinopathy - automatic segmentation of optic disc in colour fundus images, in: Proceedings of DFMA," The 2nd International Conference on Distributed Frameworks for Multimedia Applications, pp. 37-43 (2006).
- [9] C. Sinthanayothin, J.F. Boyce, H.L. Cook, T.H Williamson, "Automated location of the optic disk, fovea and retinal blood vessels from digital colour fundus image," *British Journal of Ophthalmology*, vol.83 pp.902-910 (1999).
- [10] C.I. Sanchez, R. Hornero, M.I. Lopez, J. Poza Retinal image analysis to detect and quantify lesions associated with diabetic retinopathy," *Engineering in Medicine and Biology Society, IEMBS'04. 26th Annual International Conference of the IEEE*, vol.1, pp. 1624-1627, (2004)
- [11] S.S. Basha, K.S. Prasad, "Automatic detection of hard exudates in diabetic retinopathy using morphological segmentation and fuzzy logic," *IJCSNS International Journal of Computer Science and Network Security*, vol.8 pp. 211-218 (2008).
- [12] A. Sopharak, B. Uyyanonvara, S. Barman, et al., "Automatic detection of diabetic retinopathy exudates from non-dilated retinal images using mathematical morphology methods," *Computerized Medical Imaging and Graphics*, vol. 32, pp. 720-727 (2009).
- [13] D. Satyarthi, B.A.N. Raju, S. Dandapat, "Detection of diabetic retinopathy in fundus images using vector quantization technique," *Annual India Conference (IEEE INDICON 2006)*, pp. 1-4 (2006).
- [14] H. Narasimha-Iyer, A. Can, B. Roysam, C.V. Stewart, H.L. Tanenbaum, A. Majerovics, H. Singh, "Robust detection and classification of longitudinal changes in color retinal fundus images for monitoring diabetic retinopathy," *IEEE Transaction on Biomedical Engineering*, vol. 53 pp.1084-1098 (2006).
- [15] K.A. Vermeer, M. Vos F., H.G. Lemij, et al., "A model based method for retinal blood vessel detection," *Computers in Biology and Medicine* vol. 34 pp. 209-219 (2004).
- [16] M. Niemeijer, B. Ginneken, F. Haar, "Automatic detection of the optic disc, fovea and vascular arch in digital color photographs of the retina," *Proceedings of the British Machine Vision Conference*, pp. 109-118 (2005).
- [17] K. Estabridis, R.J.P. de Figueiredo, "Automatic detection and diagnosis of diabetic retinopathy, in: *Image Processing, ICIP 2007. IEEE International Conference*, vol. 2, pp.445-448 (2007)