

Secondary Glaucoma Diagnosis Technique using Retinal Nerve Fiber Layer Veins

Gangadevi C. Bedke
M. Phil. (Research student)
Dept of CS and IT,
Dr. B. A. M. University
Aurangabad (MS)
(India)

Ramesh R. Manza Ph.D
Assistant Professor
Dept of CS and IT,
Dr. B. A. M. University
Aurangabad (MS)
(India)

Dnyaneshwari D.Patil
M. Phil. (Research student)
Dept of CS and IT,
Dr. B. A. M. University
Aurangabad (MS)
(India)

Abstract - Glaucoma is a disease of progressive optic neuropathy with loss of retinal neurons and their axons (nerve fiber layer) resulting in blindness if left untreated. This paper represents algorithm for detection of glaucoma using retinal nerve fiber layers. For this work we have used 2D median filter and HAAR wavelet transform methods. For this work we have also used Drishti-GS dataset which contains 101 glaucomatous images and HRF (High Resolution Fundus image) database. We have extracted the retinal nerve fiber layer Veins. Then we have calculated its area and diameter. On the normal database we got the 93.33% accuracy. We got 80.19% accuracy on glaucomatous images and when we have combined the normal and glaucomatous images then we got the 72.41 % accuracy.

Keywords: Retinal Nerve fiber Layer, Optic Nerve, Veins, 2D Median Filter.

1. INTRODUCTION

Among several retinal abnormalities, glaucoma is one of the leading causes of irreversible vision loss in the world. It involves a progressive degeneration of the optic nerve fibers [2]. "Glaucoma refers to a group of diseases that affect the optic nerve and involves a loss of retinal ganglion cells in a characteristic pattern, and frequently associated to an increase of intraocular pressure". If left untreated, glaucoma leads to irreversible damage of the optic nerve and to a loss of the visual field that could originate partial or total blindness. The morphological state of the optic nerve is controlled through direct observation, confocal laser scanning or stereoscopic fundus images (radiographs). However, due to the high number of patients, all these procedures are costly and need high qualified staff. The design of computerized methods for detecting this pathology in its first stages could reduce the cost of the process and the number of required specialists [3].

Glaucoma is characterized by degeneration of the retinal nerve fibers. This is usually also accompanied by an increased intraocular pressure [1]. Loss of the nerve fibers results in decrease of the RNFL thickness. Then, the connection between the photoreceptors and the brain is progressively reduced and the patient loses his vision. Pathological changes in the RNFL affects also structural

appearance of the ONH – the neuroretinal rim becomes thinner and the cup expands due to loss of the nerve fibers (Figure). The qualitative evaluation of the ONH morphology and the RNFL structure together with various perimetric tests and measurements of intraocular pressure are the common parameters that are used for glaucoma diagnosis in medical practice nowadays [1]. However, these subjective tests and visual evaluations lead to large inter- and intra-observer variability when differentiating between the normal and glaucomatous retinas [1]. Therefore, a quantitative computer-based analysis of fundus images can contribute to make general qualitative assessment more objective and reproducible. Important quantitative characteristics of the ONH (disc area, disc diameter, rim area, cup area, or cup diameter) can be derived from stereo fundus photographs [8]. Then, the well-established and well-known cup/disc ratio (C/D) can be computed from these morphological characteristics too [1]. This ratio compares diameter of the cup with the total diameter of the optic disc, i.e. the ONH. Thus, for the glaucoma assessment, C/D can quantify thinning of the neuroretinal rim. In addition, other imaging modalities can be used to establish quantitative parameters of the ONH for glaucoma diagnosis as well: CSLO (HRT), SLP (GDx), or OCT [1]. Since glaucomatous changes occur first in the retinal nerve fibers, assessment of the RNFL is much more sensitive for early detection of glaucoma than an evaluation of the ONH. Hence, current imaging modalities target on an assessment of the RNFL primarily. Among many modalities, OCT is now regarded as gold standard glaucoma diagnostic device, since it allows direct measurement of the RNFL thickness. Unfortunately, the OCT device is still quite expensive and not generally available. On the other hand, acquisition procedure by fundus camera is much faster and cheaper. There-fore, fundus camera is still regarded as a fundamental glaucoma diagnostic device [1].

Our proposed algorithm shows Secondary glaucoma diagnosis technique using retinal nerve fiber layer analysis. In this algorithm we have used the Image Processing techniques for extraction of the retinal nerve fiber layers and then classification is based on the diameter of the retinal nerve fiber layers. Basically

there are three types of retinal nerve fiber layers are present in our eyes that are Arteries, Veins and Capillaries. We have calculated the diameter of Arteries, Veins and Capillaries. We have performed the classification in two groups, in normal and Abnormal (i.e. Glaucomatous) groups. If the diameter of the retinal nerve fiber layer is not normal that is larger than normal person eye nerve fiber layer diameter then that image is glaucomatous.

In our work, we have taken the digital fundus images for retinal assessment of glaucoma. For this we have taken the DRISHTI-GS dataset which contains 101 glaucomatous fundus images [6]. We have also taken the 15 Healthy patients eye images from the High Resolution Fundus (HRF) image database [7].

The proposed algorithm shows the secondary glaucoma diagnosis technique using retinal nerve fiber layer analysis for this work we have used four steps. In first we have done the preprocessing operations and we have removed the background noise from fundus image. In second step, we have applied the HAAR wavelet. In third step, we have cropped the area of veins. In fourth step we have done the classification of all the images.

2. METHODOLOGY:

Firstly we have performed the preprocessing operations on DRISHTI-GS fundus images and high resolution fundus images. In the preprocessing color fundus image is taken. Green channel is extracted from RGB image, because green channel shows high intensity as compare to red and blue respectively. After green channel extraction histogram equalization is done for enhancement of image, after histogram equalization image is enhanced. Then we have removed the optic disc from the image because we have to extract the nerve fiber layers only. After this we have used the 2D Median filter for removing the noise. After this we have applied the Grey Threshold function and then we have applied the HAAR wavelet on the extracted image for extracting the nerve fiber layers. After Applying the HAAR wavelet function, we get four types of outputs. And from these outputs for the further processing we have used the approximate image. Then we have cropped the area of Veins, and then we have calculated its diameter.

3. PREPROCESSING

We have done preprocessing on fundus images that we have taken from the DRISHTI-GS and HRF (High Resolution Fundus) image database.

3.1 Green Channel

We have taken RGB image and then from RGB image we have taken the Green Channel, because green channel shows high intensity as compare to red and blue [4]. The formula for green channel is follows:

$$g = \frac{G}{(R + G + B)} \quad [1]$$

Here g is a Green channel and R , G and B are Red, Green and Blue respectively.

Complement function for enhancing the Nerve Fiber layers of the retina.

$$A^c = \{\omega \mid \omega \notin A\} \quad (2)$$

Here A^c is a complement is the element of A , stands for not an element of A and A is set [4].

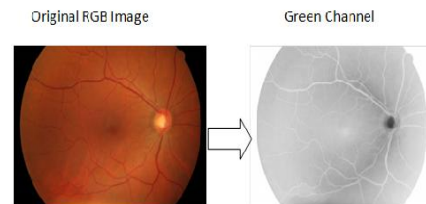

Figure 1

3.2 Retinal Nerve Fiber Layer Enhancement

3.2.1 Histogram Equalization

On the Green channel complementary image, we have applied histogram equalization function for enhancing the image.

$$h(v) = \text{round} \left(\frac{\text{cdf}(v) - \text{cdf}_{\min}}{(M \times N) - \text{cdf}_{\min}} \times (L - 1) \right) \quad (3)$$

Here cdf_{\min} is the minimum value of the cumulative distribution function, $M \times N$ gives the image's number of pixels and L is the number of grey levels.

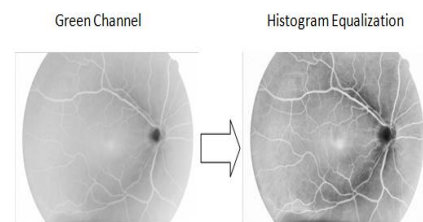


Figure 2

Then we have used the Morphological structuring element for highlighting the retinal nerve fiber layers of the retina [5].

$$I_{\text{dilated}}(i, j) = \max_{f(n, m) = \text{true}} I(i + n, j + m)$$

$$I_{\text{eroded}}(i, j) = \min_{f(n, m) = \text{true}} I(i + n, j + m) \quad [4].$$

After using the Morphological structuring element, we have used the Morphological opening function for thickening the retinal fiber layers. And then we have removed the optic disc.

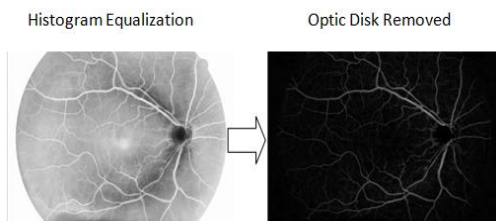


Figure 3

3.2.2 2D Median Filter

After performing Histogram equalization operation, then we have removed the optic disc from the image. After removing the optic disc, we have applied 2D Median filter operation on image for removing the noise.

$$y[m, n] = \text{median}\{x[i, j], (i, j) \in \omega\} \quad [5]$$

Here represents a neighborhood centered on location (m, n) in the image [4].

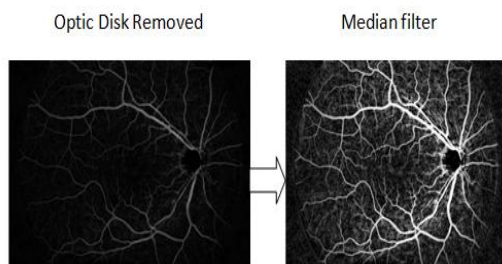


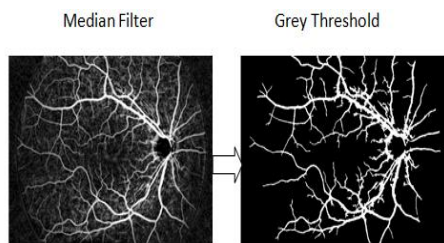
Figure 4

3.2.3 Grey Threshold

Then we have use the Threshold function for extracting the retinal blood vessels.

$$T = \frac{1}{2}(m1 + m2) \quad [6]$$

Here m1 & m2 are the Intensity Values [5].



Figure

3.2.4 HAAR Wavelet

After extracting the grey threshold of the image we have used the HAAR wavelets Mothers wavelet function [8].

$$\psi(t) = \begin{cases} 1 & 0 \leq t < 1/2, \\ -1 & 1/2 \leq t < 1, \\ 0 & \text{otherwise.} \end{cases}$$

Its scaling function $\phi(t)$ is given as

$$\phi(t) = \begin{cases} 1 & 0 \leq t < 1, \\ 0 & \text{otherwise.} \end{cases} \quad [7]$$

After using the HAAR wavelet's mother function it gives four types of output and for the further processing we are using the approximate image. Four types of output are shown in following figure.

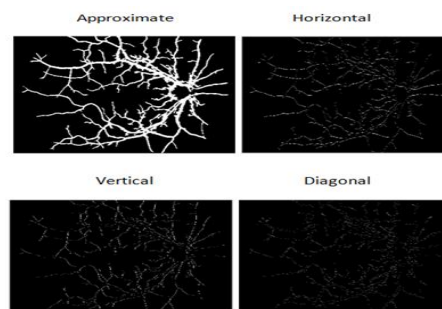


Figure 6

4. RETINAL NERVE FIBER LAYER EXTRACTION

Retinal nerve fiber layers are extracted successfully after using the HAAR wavelet. We can see here the approximate image gives the successfully extraction of nerve fibers. Nerve fiber layers are divided into three parts, Arteries, Veins, Capillaries.

- i) Arteries: Arteries are around the optic nerve.
- ii) Veins : Branches formed from arteries are Veins.
- iii) Capillaries: The Small branches from the veins are the capillaries. Capillaries are thin vessels.

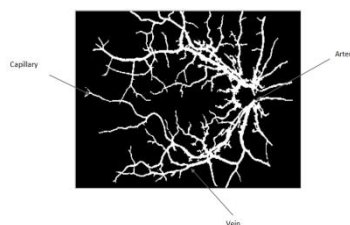


Figure 7

From the approximate image output, we have cropped the area of Veins. Then after cropping the area of veins, we have calculated its area and diameter.

$$d = \text{square root}(A/\pi) \quad [8]$$

Here A is an area and d is diameter.

5. RESULTS AND TABLES:

Firstly, we have taken the healthy patients eye fundus images from the HRF (High Resolution Fundus image) database. Then we have calculated the area and diameter of veins. Then we got the following result.

Total No Of Images	Normal	Glaucomatous
15	15	01
Result	93.33%	6.66%

Table 1. Result of Veins Extraction from HRF Database.

2. Then we have taken the glaucomatous images from the DRISHTI-GS database. And we have calculated the area of veins and its diameter. Then we got the following result.

Total No of Images	Normal	Glaucomatous
101	20	81
Result	19.80%	80.19%

Table 2. Result of veins Extraction from DRISHTI-GS Database.

3. Then we have taken the normal and glaucomatous both types of images from HRF and Drishti-GS database and then we have calculated the area and diameter of veins. From the HRF database, we have taken the 15 normal images and from DRISHTI-GS database we have taken the 101 glaucomatous images.

Total No of Images	Normal	Glaucomatous
116	32	84
Result	27.58%	72.41%

Table 3. Result of Veins Extraction from HRF and DRISHTI-GS Database.

6. CONCLUSION

In this algorithm, we have extracted retinal nerve fiber layer veins and we have calculated its area and diameter. Normal range of veins is 0.46mm-0.63mm. For extraction of veins we have used the High Resolution Fundus image database, from High Resolution database we have taken 15 healthy eye images and Drishti-GS dataset which contain 101 of glaucomatous images. On normal images we got 93.33% accuracy, and on glaucomatous images we got 80.19% accuracy. And when we have mixed the normal and glaucomatous images we got 72.41% accuracy glaucomatous images.

7. REFERENCES

1. Ing. JAN ODSTRČILÍK, "ANALYSIS OF FUNDUS IMAGES FOR RETINAL NERVE FIBER LAYER ASSESSMENT", ISBN 80-214-doplňí redakce, ISSN 1213-4198.
2. Jayanthi Sivaswamy, S.R. Krishnadas, Gopal Dutt Joshi, Madhulika Jain, Ujjwal, Syed Tabish A., "DRISHTI-GS: RETINAL IMAGE DATASET FOR OPTIC NERVE HEAD(OH) SEGMENTATION", IIIT, Hyderabad, India, Arvind Eye Hospital, Madurai, India.
3. F. Fumero, S. Alayon, J.L. Sanchez, J. Sigut, M. Gonzalez-Hernandez2," RIM-ONE: An Open Retinal Image Database for Optic Nerve Evaluation", Dept. of Systems Engineering, University of La Laguna Dept. of Ophthalmology, Hospital Universitario de Canariasfranfumero@isaatc.uil.es.
4. Manjiri B. Patwari, Ramesh R. Manza, Yogesh M. Rajput, Manoj Saswade, Neha Deshpande,"Automatic Detection of Retinal Venous Beading and Tortuosity by using Image processing Techniques", International Journal of Computer Applications (0975 – 8887) Recent Advances in Information Technology, 2014.
5. Yogesh M. Rajput, Ramesh R. Manza, Manjiri B. Patwari, Neha Deshpande, "Retinal blood vessels extraction using 2D median filter", National Conference in Advances in computing (NCAC'13), 05-06 March 2013.
6. DRISHTI-GS dataset available on URL: <http://cvit.iiit.ac.in/projects/mip/drishti-gs/mip-dataset2/Home.php>.
7. HRF database available on URL: <https://www5.cs.fau.de/research/data/fundus-images/>
8. Deepali D. Rathod, Ramesh R. Manza, Yogesh M. Rajput, Manjiri B. Patwari, Manoj Saswade, Neha Deshpande, "Localization of Optic Disc and Macula using Multilevel 2-D Wavelet Decomposition Based on Haar Wavelet Transform", International Journal of Engineering Research & Technology (IJERT), ISSN: 2278-0181 Vol. 3 Issue 7, July – 2014.